

EP CASE REPORT

Atrial tachycardia after conversion to extra-cardiac Fontan conduit: critical role of surgery-related electrical gaps

Ghassen Cheniti^{1,2*}, Xavier Iriart³, Hubert Cochet⁴, and Nicolas Derval¹

¹Department of Cardiac Electrophysiology, Hopital Haut Leveque, 33600, Bordeaux, France; ²Department of Cardiology, Hopital Sahloul, Universite de Sousse, Sousse, Tunisia; ³Department of Pediatric and Adult Congenital Cardiology, Hopital Haut Leveque, Bordeaux, France; and ⁴Department of Cardiovascular Imaging, Hopital Haut Leveque, Bordeaux, France

* Corresponding author. Tel: +33 5 786768042; fax: +33 5 57 65 65 09. E-mail address: ghassen.chniti@gmail.com

Introduction

Atrial arrhythmias in patients living with Fontan circulation are associated to worse outcome as they expose to Fontan takedown, heart failure and death.¹ The conversion of atriopulmonary anastomosis to extra-cardiac Fontan conduit with right atrial resection is reported to improve haemodynamics and reduce atrial arrhythmias.² However, this correction makes conventional percutaneous access to the atria challenging.

Case presentation

We present a 32-year-old man with a history of complex congenital heart disease including a double inlet single ventricle, a pulmonary hypoplasia, an atrial septal defect (ASD), and a transposition of great vessels. The patient benefited from an atriopulmonary connection and tricuspid annulus (TA) closure at the age of seven. The occurrence of atrial arrhythmia 18 years later motivated a first procedure of percutaneous ablation of the cavo-tricuspid isthmus. Few months later, a conversion to extra-cardiac Fontan Gore-Tex conduit with right atrial resection was performed. The patient developed 5 years later a highly symptomatic atrial tachycardia.

A percutaneous approach was performed under general anaesthesia. It was motivated by the presence on the computed tomography (see [Supplementary material online, Figure S1](#)) of an area of adherence between the Gore-Tex conduit and the right atrial wall (*Figure 1A*). The trans-conduit puncture was performed using a conventional needle (BRK, Abbott) under transoesophageal echocardiographic control. We used a high-density mapping catheter (Orion, Boston Scientific) to map the tachycardia. The presence of a large ASD allowed complete

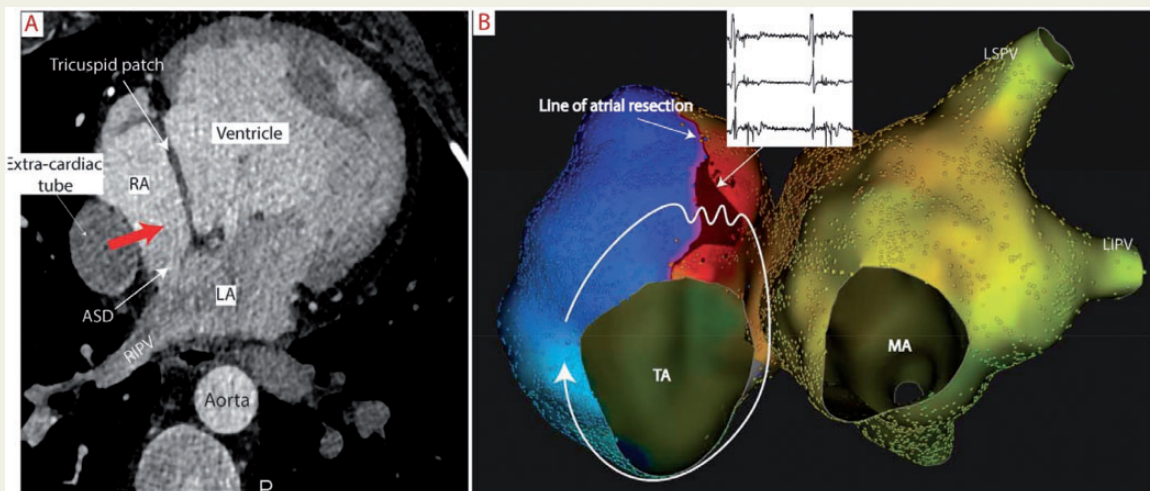


Figure 1 (A) Computed tomography shows the apposition of the tube and right atrial wall, which predicts a safe trans-conduit puncture (red arrow). (B) LAO view of the right and left atria showing a peri-tricuspid macroreentrant tachycardia. The tachycardia uses a gap with a slow conduction on an anterior line of block. ASD, atrial septal defect; LA, left atrium; LAO, left anterior oblique; LIPV, left inferior pulmonary vein; MA, mitral annulus; RA, right atrium; RIPV, right inferior pulmonary vein; TA, tricuspid annulus.

bi-atrial mapping. The line of atrial resection was identified as a line of low voltage and electrical block (*Figure 1B*). The activation map of the tachycardia identified a macro-reentrant clockwise peri-tricuspid flutter. The circuit used two electrical gaps both located between the line of atrial resection and the TA. Ablation using an irrigated catheter and targeting the anterior gap terminated the tachycardia in 9 s. The anterior line was blocked after connection to the TA (see [Supplementary material online, Figure S2](#)). Echographic control performed after the catheter withdrawal and the following days eliminated any pericardial effusion. The patient did well after the procedure without tachycardia recurrence at a follow-up of 5 months.

Conclusion

This case demonstrates the creation of a substrate sustaining atrial re-entrant arrhythmias after right atrial resection in patients undergoing conversion of atriopulmonary anastomosis to extra-cardiac Fontan conduit. This situation is also encountered in patients with grown-up congenital heart disease who undergo surgical repair. The association of (i) large atriotomy and (ii) electrical gaps with slow conduction between the lines of atriotomy and the anatomical barriers (e.g. TA) represent the ideal substrate for re-entrant atrial tachycardias. Per-operative local ablation aiming to block these electrical gaps would prevent surgery-related re-entrant atrial arrhythmias and avoid complex percutaneous interventions. The benefit of Per-operative ablation was well demonstrated in previous studies³ and such strategy should be encouraged.

Supplementary material

[Supplementary material](#) is available at *Europace* online.

Conflict of interest: none declared.

References

1. Carins TA, Shi WY, Iyengar AJ, Nisbet A, Forsdick V, Zannino D et al. Long-term outcomes after first-onset arrhythmia in Fontan physiology. *J Thorac Cardiovasc Surg* 2016;**152**:1355–63.e1.
2. van Son JA, Mohr FW, Hamsch J, Schneider P, Hess H, Haas GS. Conversion of atriopulmonary or lateral atrial tunnel cavopulmonary anastomosis to extracardiac conduit Fontan modification. *Eur J Cardiothorac Surg* 1999;**15**:150–7; discussion 157–8.
3. Mavroudis C, Backer CL, Deal BJ. Late reoperations for Fontan patients: state of the art invited review. *Eur J Cardiothorac Surg* 2008;**34**:1034–40.